



Circular abdominoplasty after massive weight loss: Is it a risky procedure?

Ali Modarressi*, Eva Meia Rüegg, Thierry Bezzola, Brigitte Pittet-Cuénod

Division of Plastic, Reconstructive and Aesthetic Surgery, Geneva University Hospitals, University of Geneva, Faculty of Medicine, Geneva, Switzerland

Received 4 December 2015; accepted 22 May 2016

KEYWORDS

Body contouring;
Circular
abdominoplasty;
Massive weight loss;
Bariatric surgery;
Complication;
Circular belt
lipectomy

Summary *Introduction:* Most post-bariatric patients seek body contouring procedures to correct skin excess after massive weight loss. Among these procedures, some surgeons are still wary of circular abdominoplasty, mainly because it is considered a major intervention associated with a high complication rate. The aim of this study was to assess the complication rate of circular abdominoplasty performed on patients presenting with massive weight loss, with a particular emphasis on patient selection and surgical technique.

Methods: Fifty-six consecutive patients who underwent circular abdominoplasty following massive weight loss between January 2001 and March 2015 were included in the study. The indications for the procedure were abdominal skin excess extending to the flanks and the posterior region of the lower trunk. Data were collected retrospectively through medical charts and photographs.

Results: Forty-nine patients were female. The mean age was 39.8 years, with a mean preoperative body mass index of 25.7 kg/m². The mean time between bariatric surgery and circular abdominoplasty was 3.3 years. The overall complication rate was 23.2%, mostly minor, with only one (1.7%) early surgical revision under local anesthesia for delayed wound healing. Blood transfusion was required for 8.9% of patients.

Conclusion: Patient selection (e.g., body mass index < 30 kg/m²), precise preoperative planning and markings, and simple and careful surgical technique with minimal liposuction and undermining are crucial. Ensuring these key factors renders circular abdominoplasty a reliable and safe procedure, with low complication rates.

© 2016 British Association of Plastic, Reconstructive and Aesthetic Surgeons. Published by Elsevier Ltd. All rights reserved.

* Corresponding author. Division of Plastic, Reconstructive and Aesthetic Surgery, Department of Surgery, Geneva University Hospitals, 4 Rue Gabrielle-Perret-Gentil, 1211, Geneva 14, Switzerland. Tel.: +41 22 372 7997; fax: +41 22 372 8005.

E-mail address: ali.modarressi@hcuge.ch (A. Modarressi).

Introduction

Following massive weight loss (MWL) mainly after bariatric surgery, most patients seek body-contouring procedures to correct contour deformities due to sagging skin.¹ These procedures have been found to further improve quality of life, satisfaction rate,² and long-term weight control.³

However, in some patients with lateral or posterior skin and fat excess, classical abdominoplasty fails to restore a satisfactory truncal contour⁴ and may even accentuate the lateral excess. Thus, numerous extended abdominoplasty techniques, such as circular abdominoplasty, belt lipectomy, torsoplasty, or body lift, have been developed in order to improve the contour of the back, buttocks, and flanks at the same time as the anterior part of the abdomen is operated. The first circular dermolipectomy was attributed to Somalo in 1940. Gonzalez-Ulloa published the belt lipectomy technique in 1961 with a high excision in the back and vertical wedge resection.⁵ In the following years, technical improvements were made to this latter method, and wedge excisions were abandoned.⁶ In the 1990s, Lockwood described various lower body-lift procedures, all of which include lateral thigh undermining down to the knees.^{7–9} More recently, Pascal and Le Louarn published their technique advocating only limited lateral thigh mobilization, the use of suspension and mattress sutures, and gluteal augmentation by autologous flaps.^{10,11}

The terminology of circular procedures is still debated. According to the definition by Hamra, “the body-lift is a combination of circumferential abdominoplasty or ‘belt lipectomy’ with lateral thigh lift”; therefore, the term “body lift” should be used only when thigh undermining is performed. Circular abdominoplasty involves horizontal excision and low incision lines in the back, flanks, and groin area, similar to the body lift, but without lateral thigh undermining; it allows a good vertical lift of these regions. Belt lipectomy involves higher incisions in the back and undermining of the upper dorsal flap. This surgery usually creates a more defined waistline, and it can also address back rolls. However, the drawbacks are a more conspicuous scar line and higher risks of seroma formation.¹² The heterogeneity of surgical techniques and lack of data reported in the literature make the comparison between techniques difficult; thus, more standardized procedures and studies are required. Moreover, these procedures are still not widely accepted, mainly because they are still considered time consuming and difficult to perform. They are also well known for their high complication rate of up to 76%,¹³ mostly related to seroma and wound healing problems.^{14,15} In some studies, almost half of all patients required a blood transfusion.^{16,17} In this paper, we assess the complication rate of circular abdominoplasty on patients presenting with MWL following bariatric surgery, focusing particularly on patient selection and surgical technique.

Patients and methods

This study was approved by the local ethical committee. All patients undergoing circular abdominoplasty following MWL after bariatric surgery or diet between January 2001 and

March 2015 were included in the study. The indication for circular abdominoplasty was MWL, which resulted in excess skin of the abdomen extending to the flanks and posterior region of the lower trunk. As suggested by Shermak et al., MWL was defined as $\geq 50\%$ loss of the excess weight.¹⁸ Surgery was performed at least 12 months after bariatric surgery and after the patient’s weight had been stable for >6 months. Patients were examined at least twice before surgery. All operations and follow-up were performed in a single public university hospital.

Data collection

General patient data including age, gender, body mass index (BMI) before and after bariatric surgery at the time of circular abdominoplasty, American Society of Anesthesiologists (ASA) score, tobacco use, presence of arterial hypertension or diabetes mellitus, and current medication were collected from their medical files. A detailed description of the operation, as well as complications associated with the surgical procedure, was recorded.

Preoperative markings

Preoperative markings are essential for this procedure as they define the final position of the scar. As described by Pascal and Le Louarn,¹¹ they were made preoperatively in the upright and supine position. Vertical lines were drawn laterally along the midaxillary line, as well as on the mid-lines of the back and the abdomen. The lateral line divides the ventral and dorsal regions, which carry opposite vectors of the stretching in this procedure. The stretching was performed downward in the abdominal region and upward in the gluteal region. The future scar line was initially defined laterally and posteriorly, according to the patient’s preferences and underwear habit. The superior and inferior extent of the resection in the back, buttocks, and flanks were estimated using the “pinch test” around the prefixed line of closure, corresponding to the superior line dorsally and the inferior line ventrally. On the back, the superior resection should be conservative as the skin in this area is rather fixed. Anteriorly, a pen mark was placed approximately 7 cm above the anterior vulvar commissure in female or the base of penis in male, to define the pubis lift. A horizontal line of 7 cm on each side was then drawn and continued in a curvilinear fashion below the inferior abdominal fold to join the lateral incisions. At this point, a verification of lateral symmetry was necessary. The superior excision line of the abdomen was temporarily drawn at the level of the umbilicus or just above and was ultimately defined during surgery after the superior undermining (Figure 1).

Surgical technique

Under general anesthesia, a single dose of 1.5 g cefuroxime was administered intravenously 30 min before incision, a urinary catheter inserted, and a pneumatic calf compression device installed. Surgery was initially performed in the prone position. After disinfection and draping, the incision lines were infiltrated with a saline solution containing

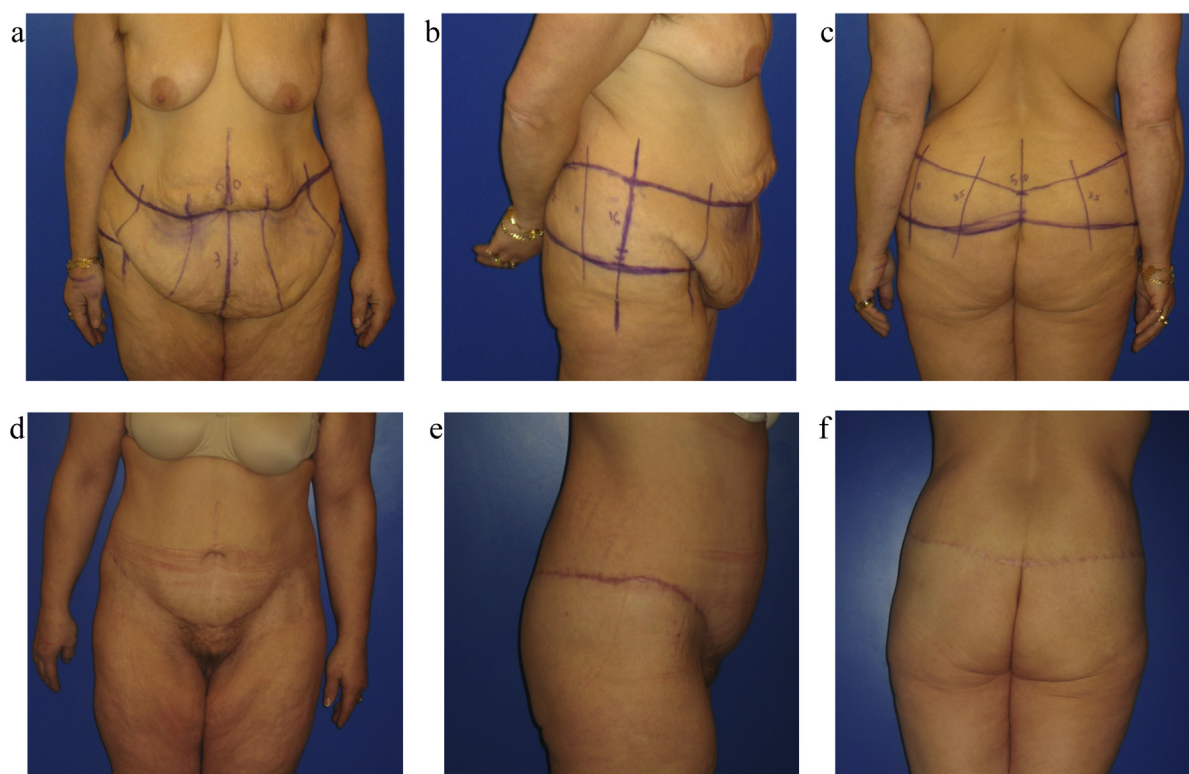


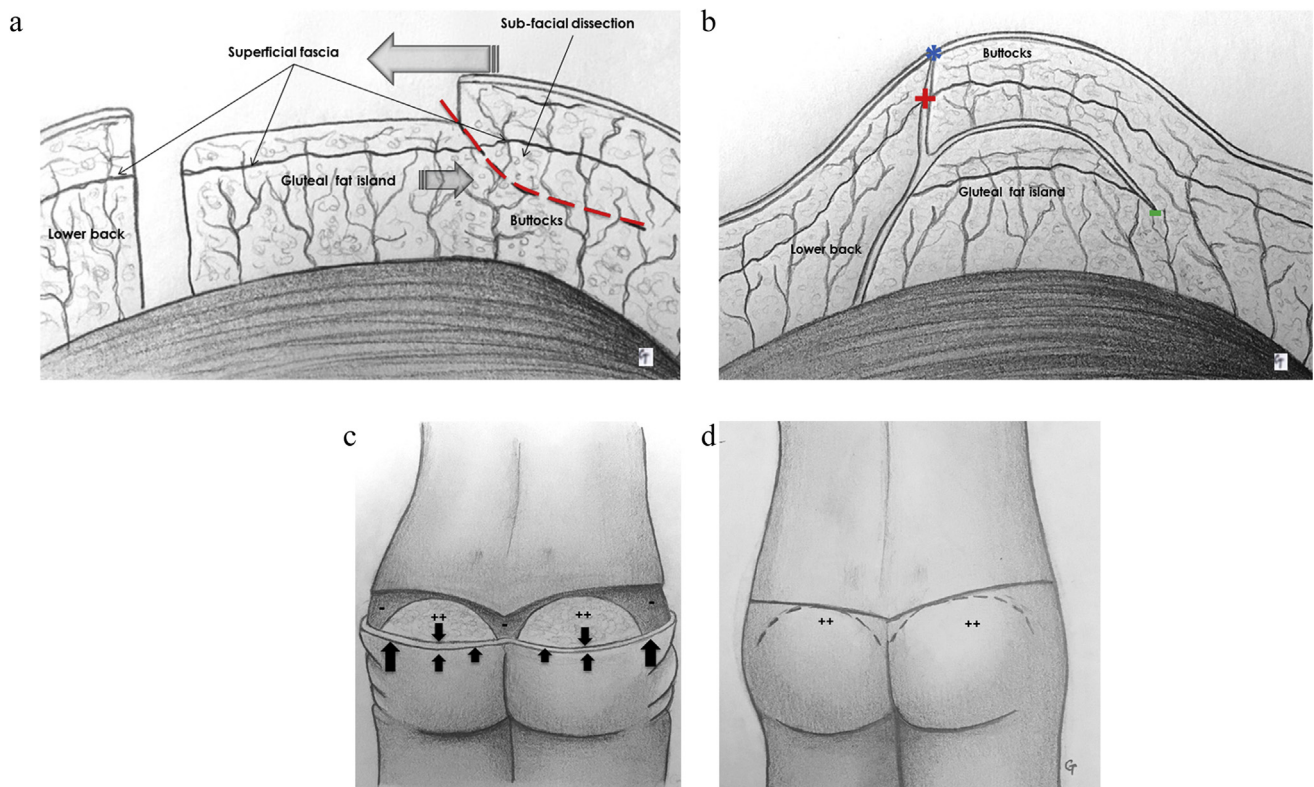
Figure 1 Example of circular abdominoplasty after massive weight loss: A 51-year-old patient presenting with circular truncal skin excess 5 years after Roux-en-Y gastric bypass with 44-kg weight loss. For >6 months, she had a stable weight of 67 kg and BMI 28.25 kg/m² (pre-gastric bypass weight 111 kg and BMI 47 kg/m²). *a,b,c*) Preoperative markings: Vertical lines were drawn laterally, on the midline of the back and the abdomen. The future scar line was initially defined laterally and posteriorly, according to the patient's preferences and underwear habit. The superior and inferior extent of the resection in the back, buttocks, and flanks were estimated using the "pinch test" around the prefixed line of closure. Anteriorly, 7 cm above the anterior vulvar commissure, a horizontal line of 7 cm on each side was then drawn and continued in a curvilinear fashion below the inferior abdominal fold to join the lateral incisions. The superior excision line of the abdomen was temporarily drawn at the level of the umbilicus and was ultimately defined during surgery after the superior undermining. During the circular abdominoplasty, 1170 g of skin excess (40 × 11 cm) was resected from the posterior part and 2440 g (90 × 36 cm) from the anterior abdomen, without any other associated procedure. *d,e,f*) 1 year after circular abdominoplasty without any complication: 64 kg, BMI 27 kg/m². Later scars are usually more "inflammatory," but as they will reduce over time, further treatment is not required.

epinephrine (500 ml NaCl solution with 1 mg of adrenaline). Following the preoperative markings, an en bloc resection of the skin and fat from the midline to the lateral vertical line over the iliac crests was performed with a scalpel, leaving a small amount of fat over the muscular fascia (deep fascia). In the case of poor gluteal volume, fat was completely preserved in the gluteal region and used for buttock augmentation. In this case, a full-thickness resection (i.e., skin and fat down to the deep fascia) was performed only on the lateral and medial part of the gluteal fat island. Over the gluteal fat island designed as a semi-circular shape, only the skin (i.e., epidermis and dermis) was resected, and all fat layers including the superficial fascia were preserved. For this autologous gluteal augmentation, instead of flipping a gluteal flap over itself as described by Le Louarn and Pascal,¹⁰ we just pushed the inferior skin flap upward over the gluteal fat island, and we slightly glided the gluteal fat island downward. Only minimal undermining was required, in a layer above the deep muscular fascia of the inferior skin flap, without any additional dissection of the fat island. The inferior border of the

gluteal fat island was then fixed with 2/0 absorbable sutures in the inferior part of the neo-buttocks. It allowed the gluteal fat island to be placed in the right position in the buttocks (Scheme 1).

After meticulous hemostasis, a three-level suture was performed: 1) at the superficial fascia level, using 0 or 2/0 absorbable sutures according to the tension (e.g., Vicryl® or PDS®); 2) subcutaneous separate stitches with 2/0 and 3/0 absorbable sutures (e.g., Monocryl®); and 3) at the dermis level using a running suture with 3/0 absorbable sutures (e.g. Monocryl®). The lateral dog-ears were temporarily closed with staples and the suture line covered with sterile dressings. The patient was then turned to a supine position in order to disinfect and drape the surgical field.

A classical abdominoplasty with umbilical translocation and limited superolateral subcostal undermining was performed. The abdominal flap was dissected using a scalpel, sparing the deep fascia over the muscle. All perforating vessels were either cauterized or ligated, depending on their diameter. Fascial plication using a no. 1 slow absorbable suture (e.g., Maxon®) was performed for



Scheme 1 Autologous gluteal augmentation a,b) Tangential cut view: gluteal fat island is prepared after excision of epidermis and dermis over the superficial fascia. After undermining in a layer below the superficial fascia of the "buttocks," the "buttock" skin is glided upward and the gluteal fat island pushed downward and fixed with sutures in the caudal part of the buttocks (–). Superficial fascia of the "buttocks" is sutured with the superficial fascia of the lower back (+) and skin is closed over the gluteal fat island (*). c,d) Back view: gluteal fat island (++) is prepared as a semi-circular shape. On the medial and lateral parts, a full-thickness resection is made (–). After caudal undermining, the gluteal fat island is pulled down and the skin is glided upward and closed.

patients presenting rectus abdominis muscles diastasis. In the case of incisional or umbilicus hernia, open hernia repair was performed with synthetic mesh (e.g., polypropylene). The umbilicus was dissected in a chevron shape and sutured to the rectus abdominis sheath with 3/0 non-resorbable monofilament sutures (e.g., Prolene®). The resection of skin excess was performed in a semi-seated position. In total, four drains were placed, two in the back and two in the front. Wound closure was performed in two layers with 3/0 absorbable sutures (e.g., Monocryl®) without any high-tension or mattress sutures. Finally, the dressing was completed with a removable abdominal compression garment.

Postoperative care and follow-up

All patients were hospitalized after surgery. Hip and knee flexion was maintained at 30° in bed during hospital stay. Pneumatic calf compression was left in place until the patient's first mobilization. Postoperative blood counts were performed within the first 2 days after surgery. Low molecular weight heparin was administered subcutaneously once daily at a thromboprophylactic dose beginning on the day of surgery and continued until hospital discharge. Antibiotic therapy was continued until drain removal only if

abdominal wall repair was performed using a mesh. The drain was usually removed if the flow was <20 ml/24 h. After discharge, patients were encouraged to wear a removable abdominal belt for 6 weeks. In the absence of any complications, outpatient controls were scheduled 2 and 6 weeks after the procedure, as well as 3, 6, and 12 months postoperatively, or on a more frequent basis if required.

Charts were reviewed assessing blood transfusion during hospital stay, as well as immediate and delayed complications, such as hematoma or seroma formation, wound dehiscence, or the presence of partial skin flap necrosis and infection. Diagnosis of infection and seroma was generally based on clinical signs and confirmed by microbiological tests and ultrasound.

Results

Fifty-six patients underwent circular abdominoplasty, 49 of whom were women. Before MWL, all were morbidly obese with a mean BMI of 45.8 kg/m². For those who underwent bariatric surgery (e.g., 95% of patients), the mean time between bariatric surgery and circular abdominoplasty was 3.3 years (range, 1–7.2 years). Fifteen patients (26.7%) were active smokers. Seven patients had arterial

hypertension and five patients had type II diabetes. The mean age was 39.8 years (range, 18–62 years) and mean BMI was 25.7 kg/m² (range, 19.3–32.0 kg/m²). Table 1 indicates the different types of bariatric surgery, ASA score, medication at the time of surgery, as well as preoperative hemoglobin values.

Table 1 Patient characteristics (*n* = 56).

| | Value (range) |
|---|------------------|
| Age (years) | 39.8 (18–62) |
| BMI before weight loss (kg/m ²) | 45.8 (40.7–64.0) |
| BMI after weight loss (kg/m ²) | 25.7 (19.3–32) |
| MWL method | |
| RYGBP laparotomy | 15 |
| RYGBP laparoscopy | 33 |
| Gastric banding | 5 |
| Diet | 3 |
| ASA 1 | 12 |
| ASA 2 | 44 |
| Iron substitution | 31 |
| Folate and vitamin B12 substitution | 18 |
| Preoperative hemoglobin (g/dL) | 13.2 (10.4–14.9) |
| Duration of surgery (hours) | 5.2 (3.2–7.3) |
| Hospital stay (days) | 7 (5–25) |

BMI, body mass index; MWL, massive weight loss; RYGBP, Roux-en-Y gastric bypass; ASA, American Society of Anesthesiologists.

Table 2 Concomitant procedures.

| Procedure | No. patients |
|-----------------------------------|--------------|
| Rectus abdominis fascia plication | 41 |
| Incisional hernia repair: suture | 7 |
| Incisional hernia repair: mesh | 4 |
| Autologous gluteal augmentation | 32 |
| Medial thigh lift | 5 |
| Mastopexy | 4 |
| Liposuction | 11 |
| Augmentation mammoplasty | 1 |
| Brachioplasty | 3 |

Surgical data

The resection weight ranged from 980 to 7975 g, with a mean weight of 2932 g. The mean resected skin length was 24 cm ventrally (range, 11–38 cm) and 13 cm in the back (range, 7–25 cm). Concomitant procedure(s) were performed in 31 (55%) patients (Table 2). The overall mean surgical duration was 5.2 h and the mean length of hospital stay was 7 days.

Complications

No general complications occurred, such as deep venous thrombosis, pulmonary embolism, or pneumonia. The overall complication rate was 23.2% with nonsignificant difference between smokers and nonsmokers (26.7% vs. 22%). appeared at the same time as wound dehiscence and evacuated spontaneously in two patients, whereas two others required a needle aspiration. Four infections (7.1%) were observed and treated conservatively with antibiotics. No skin flap necrosis was observed. Seven patients (12.5%) suffered from localized delayed wound healing, and only one (1.8%) needed early surgical revision under local anesthesia. The mean postoperative hemoglobin concentration was 9.4 g/dL (range, 6.4–13.5 g/dL; mean drop, 3.8 g/dL). Due to symptomatic anemia (i.e., shortness of breath, palpitations, and weakness), five female patients (8.9%) required a blood transfusion during their stay (two units of blood for each patient). All five patients underwent circumferential abdominoplasty with autologous gluteal augmentation; in two of these patients, the procedure was combined with a medial thigh lift. Blood transfusion was significantly more likely with autologous gluteal augmentation (5/32 vs. 0/24). Other concomitant procedures such as medial thigh lift increased the blood transfusion risk but nonsignificantly (*p* = 0.09). The mean tissue resection weight of patients requiring blood transfusion was higher than those who did not need blood transfusion (4353 vs. 2830 g, *p* = 0.07).

The postoperative results were satisfactory for most patients. Four patients (7.1%) underwent secondary delay revision, mostly by combined procedures: three scar

Table 3 Complications.

| Complications <i>N</i> (%) | Total <i>n</i> = 56 | Nonsmokers <i>n</i> = 41 | Smokers <i>n</i> = 15 |
|----------------------------|---------------------|--------------------------|-----------------------|
| Overall complication | 13 (23.2%) | 9 (22%) | 4 (26.7%) |
| Thromboembolic event | 0 | 0 | 0 |
| Blood transfusion | 5 (8.9%) | 4 (9.8%) | 1 (6.7%) |
| Wound infection | 4 (7.1%) | 3 (7.3%) | 1 (6.7%) |
| Skin necrosis | 0 | 0 | 0 |
| Hematoma | 2 (3.5%) | 2 (4.8%) | 0 |
| Seroma | 4 (7.1%) | 4 (9.8%) | 0 |
| Wound dehiscence | 7 (12.5%) | 4 (9.8%) | 3 (20%) |
| Needing early surgery | 1 (1.8%) | 1 (2.4%) | 0 |
| Secondary delayed revision | 4 (7.1%) | 3 (7.3%) | 1 (6.7%) |
| Scar corrections | 3 (5.3%) | 2 (4.9%) | 1 (6.7%) |
| Lipoaspiration | 2 (3.6%) | 2 (4.9%) | 0 |
| Vertical skin resection | 3 (5.3%) | 3 (7.3%) | 0 |

revision, two lipoaspiration, and three vertical skin resection for horizontal excess skin (Table 3).

Discussion

At present, plastic surgeons commonly face a large number of body-contouring requests, mainly because of the increasing number of bariatric procedures performed due to epidemic obesity. An extended dermolipectomy should be considered for patients with lateral and back skin excess after MWL. The length of the procedure (6–9 h according to Lockwood's first publications), extensive scarring, as well as the high complication rates reported in the literature (Table 4) are responsible for the poor outcomes of this operation¹⁹ and still discourage many surgeons.

Our study analyzed patients who underwent circular abdominoplasty after MWL. Most (94.6%) had undergone bariatric surgery, which is known to be associated with increased wound infections and a delayed healing rate consecutive to induced nutritional deficiencies and poor tissue quality.^{20–22} However, in our series, the overall complication rate was low (23.2%) compared to other studies, which reported rates up to 76% (Table 4). Body lift seems to be associated with a higher risk of skin necrosis (up to 9.5%) or wound dehiscence (up to 63%) (Table 4). This can be explained by the tension applied on skin flaps, especially over the thighs, the hips being generally abducted for resection and closure. We did not observe any skin necrosis, and delayed healing was seen in only 12.5% of patients. Only one patient needed early surgical wound revision under local anesthesia, which represents a low revision rate. These good results were obtained, despite 26.7% of active smokers present in our cohort. Kitzinger et al. concluded that tobacco use presents a more than fivefold potential risk of major complications following lower body lift.²³ In our study, although the complication rate was higher in smokers than in nonsmokers (26.7% vs. 22%), we did not find any significant increase. This result could be explained either by the small number of patients in each group or by the fact that the surgical procedure was adapted for patients who were active smokers (e.g. less skin resection, combined procedures avoided). Therefore, a more specific study particularly assessing the effect of tobacco on circular abdominoplasty complications is needed.

Seroma is one of the main complications and concerns after body lift. Thigh undermining is known to increase the incidence of seromas.²⁴ To reduce the seroma rate, different approaches have been proposed, such as quilting sutures,¹¹ fibrin glue application,²⁵ or preservation of the superficial fascia.²⁶ We did not use any of these recently described techniques but, as suggested by Pascal and Le Louarn, the undermining zone was limited to the resection area in the sub-umbilical region and minimal on the supra-umbilical part.¹¹ Furthermore, few patients (19.6%) underwent an associated liposuction. We observed only four cases of anterior localized seroma (7%), which were treated with one aspiration and no additional surgical procedure. We consider that the use of scalpel instead of electrocautery for incision and dissection may also explain our rather low seroma and wound complication rate.

Although we do not perform lateral thigh undermining, we still observed a satisfactory improvement in antero-lateral thigh and buttock contour, and in cosmetic results. Extended scars, which could make patients and some surgeons apprehensive, are generally well accepted with regard to previous scars and new contour definition. Few cases of scar enlargements or hypertrophy were observed in our cohort, and the patients were able to hide their circular scar in their usual underwear. A total of 17 patients underwent further body-contouring procedures, such as medial thigh lift, mastopexy, brachioplasty, or face lift. Three underwent additional vertical truncal skin resection during the subsequent procedures because of persistence of horizontal skin laxity, a well-known problem regardless of the chosen technique.²⁷ Further studies are needed to assess particularly the satisfactory rate and long-term outcomes of this procedure.

Weight status is a major risk factor for body contouring. Even after MWL, formerly morbidly obese patients rarely achieve a "normal" BMI ($<25 \text{ kg/m}^2$), and most candidates for circular abdominoplasty are still overweight. Obese patients are at a higher risk of hematoma/seroma formation, skin necrosis, infection, and delayed wound healing.^{24,28,29} According to Nemerofsky and Aly, the threshold BMI to perform circular body contouring is 35 and 32 kg/m^2 , respectively.^{12,24} One specific complication, venous thromboembolism, is also significantly increased if the BMI exceeds 30 kg/m^2 (Table 4).³⁰ Interestingly, some studies have even shown that the complication rate following body contouring is more significantly associated with maximum BMI before bariatric surgery than with the BMI at the time of body contouring.^{23,24,31} This association could be due to the structural skin damage induced by obesity,^{32,33} which leads to delayed wound healing or skin necrosis. Constantine et al. demonstrated that wound problems after body contouring are directly related to the quantity of weight loss (odds ratio, 3.98: weight loss >45 vs. <45 kg), particularly in patients who undergo gastric bypass (odds ratio, 3.01).²² In our cohort, the patient BMI before bariatric surgery was relatively high (mean BMI, 45.8 kg/m^2). However, the BMI ranged from 19.3 to 32 with a mean of 25.7 kg/m^2 at the time of circular abdominoplasty, the lowest value reported among published studies. Importantly, we did not observe any major complications, such as deep venous thrombosis or pulmonary thromboembolism, and our overall complication rate was lower.

Although 86% of patients had undergone a Roux-en-Y gastric bypass, a restrictive and malabsorptive procedure causing iron, folate, and vitamin B12 deficiencies, the blood transfusion rate was relatively low (8.9%) compared to most other studies (Table 4).^{9,11,16,34} One reason may be that anemia, especially due to iron deficiency, was closely monitored by our multidisciplinary bariatric surgery team during the follow-up after the procedure and iron substitution provided when necessary. As a result, the preoperative red blood cell counts showed normal hemoglobin values (mean 13.2 g/dL), and no preoperative blood transfusions or autotransfusions were necessary. Another method of limiting the incidence of blood transfusion is reducing perioperative blood loss by meticulous preoperative planning of the incision lines in order to avoid multiple skin re-excisions during surgery and to perform pre-

Table 4 Other published studies (1999–2015) on complications after circular body contouring compared with our study.

| Paper (first author) ^{REF} | Van Geertruyden ⁸ | Aly ¹⁶ | Van Huizum ³³ | Rohrich ³⁵ | Dini ^a | Vico | Koller ²⁵ | Pascal ²⁶ | Nemerofsky ²³ | Jones ¹² | Hurwitz ^{5; b} | Pilone ^{24; c} | Kitzinger ²² | Buchanan ³⁴ | de Runz | Modarressi |
|-------------------------------------|------------------------------|-------------------|--------------------------|----------------------------|-------------------|-----------|----------------------|----------------------|--------------------------|---------------------|-------------------------|-------------------------|-------------------------|------------------------|---------|-------------------------|
| Year of publication | 1999 | 2003 | 2005 | 2006 | 2008 | 2009 | 2011 | 2004 | 2006 | 2008 | 2008 | 2014 | 2013 | 2013 | 2015 | 2016 |
| Type of procedure | Circumfer. torsoplasty | Belt lipectomy | | Circumferential Contouring | | Body lift | | Body lift | | Body lift | | Lower body lift | | Lower body lift | | Circular abdominoplasty |
| Number of patients | 30 | 32 | 21 | 151 | 41 | 23 | 50 | 100 | 200 | 16 | 75 | 15 | 50 | 16 | 55 | 56 |
| Mean BMI | ? | 30.3 | 28.1 | ? | 32 | 29.8 | 27.9 | ? | 29.2 | 26.7 | 29.36 | 36.4 | 27.8 | 30.89 | 28.2 | 25.7 |
| Tobacco use (%) | 10 | 3.1 | 43 | ? | 44 | ? | ? | ? | 18 | 45.5 | | 46 | 38 | ? | 9 | 26.7 |
| Overall complication rate | 13.3 | ? | 38.1 | 28.5 | 46 | 34.8 | ? | ? | 50 | 44 | 76 | ? | 70 | ? | 40 | 23.2 |
| Thromboembolic | 3.3 | 9.4 | 0 | 2 | 0 | 8.7 | ? | 0 | 2 | 0 | 1 | ? | 0 | 0 | 1.8 | 0 |
| Seroma | 6.7 | 37.5 | 0 | 14.6 | 28 | 4 | 8 | 0 | 16.5 | 25 | 37 | 53.3 | 34 | 31 | 9.1 | 7 |
| Infection | 0 | 9.4 | 19 | 0.5 | ? | 4 | 0 | 4 | 3.5 | 0 | 0 | 20 | 8 | 47 | 1.8 | 7 |
| Skin necrosis | 0 | 3.1 | 0 | 1.3 | ? | 4 | 0 | 0 | 9.5 | 0 | ? | 0 | 2 | ? | 1.8 | 0 |
| Wound dehiscence | 6.7 | 9.4 | 28.6 | 1.3 | 16 | 13 | 0 | ? | 32.5 | 12.5 | 13 | 33.3 | 60 | 62 | 16.4 | 12.5 |
| Revision surgery (%) | 3.3 | ? | 4.8 | 5.3 | 3.6 | ? | ? | ? | ? | 12.5 | 41 | ? | 10 | 37.5 | 9.1 | 8.9 |
| Blood transfusion (%) | 43.3 | 12.5 | 19 | ? | 0 | 17 | ? | 15 | 15.5 | 0 | 1.5 | 26.6 | ? | 0 | 21.8 | 8.9 |
| Duration of surgery (hours) | 3.5 | 5.75 | 2.2 | 3.4 | 3.8 | 5 | 3.8 | 4.5 | 4.2 | 4.2 | 8.4 | ? | 5.2 | ? | 4.85 | 5.2 |
| Mean hosp. stay (days) | 12 | ? | 8 | 2.1 | 4.8 | 8.8 | ? | ? | 3 | 3.5 | ? | 4.5 | ? | ? | 6.1 | 7 |

^a Fibrin glue was used in all cases.^b Procedures were performed in one, two, or three stages.^c Seroma rate was 6.6% with fibrin glue versus 53.3% without.

incisional infiltration with saline containing epinephrine, as suggested by Pascal and Le Louarn.²⁷

Compared to other series, our mean hospital stay (7 days) was long. This can be attributed to two facts: all patients had suction drains, and they were only discharged when these drains were removed (<20 ml/day of serum). This may also explain the lower rate of seroma. Moreover, most procedures were covered by health insurances and the reimbursement was based on a "diagnosis-related group" (DRG) charge. Therefore, patients may stay in hospital for a longer time for their own comfort, to remain rested, and to resume their daily activities at a later stage, thus leading to fewer complications. At present, we attempt to reduce the hospital stay to decrease nosocomial infection and thromboembolic complications and to reduce the associated costs. As demonstrated by Buchanan et al., these procedures could even be performed safely and effectively in some selected patients in an outpatient setting.³⁵

Conclusion

In our experience, circular abdominoplasty is a reliable procedure, contrary to popular opinion. Patient preselection is crucial for reducing the complication rate. Patients who have lost <45 kg,²² but achieved a low BMI (<30 kg/m²) at the time of body contouring, present a lesser operative risk and obtain a better aesthetic result. Precise preoperative drawings are crucial, with "measure twice and cut once" being an important principle. It helps reduce the surgery time and blood loss and offers more satisfactory aesthetic results. A surgical technique with minimal undermining and liposuction could reduce further complications. Using a scalpel instead of electrocautery could also be considered, which has to be confirmed by other studies, to decrease wound healing problems and the seroma rate. If these key factors are ensured, circular abdominoplasty is a safe procedure with a low complication rate and high patient satisfaction.

Conflicts of interest

None.

Funding

None.

Acknowledgments

The authors thank Dr Céline Thomet for the design of Scheme 1 and Dr. Julien Baudoin for his help in collecting patient data.

References

- Kitzinger HB, Abayev S, Pittermann A, et al. After massive weight loss: patients' expectations of body contouring surgery. *Obes Surg* 2012;22:544–8.
- Modarressi A, Balague N, Huber O, Chilcott M, Pittet-Cuenod B. Plastic surgery after gastric bypass improves long-term quality of life. *Obes Surg* 2013;23:24–30.
- Balague N, Combescure C, Huber O, Pittet-Cuenod B, Modarressi A. Plastic surgery improves long-term weight control after bariatric surgery. *Plastic Reconstr Surg* 2013;132:826–33.
- Stewart KJ, Stewart DA, Coghlan B, Harrison DH, Jones BM, Waterhouse N. Complications of 278 consecutive abdominoplasties. *J Plastic Reconstr Aesthetic Surg* 2006;59:1152–5.
- Gonzalez-Ulloa M. Belt lipectomy. *Br J Plast Surg* 1960;13:179–86.
- Aly AS, Cram AE, Chao M, Pang J, McKeon M. Belt lipectomy for circumferential truncal excess: the University of Iowa experience. *Plast Reconstr Surg* 2003;111:398–413.
- Lockwood T. Lower body lift with superficial fascial system suspension. *Plast Reconstr Surg* 1993;92:1112–22. discussion 23–5.
- Lockwood T. The role of excisional lifting in body contour surgery. *Clin Plastic Surg* 1996;23:695–712.
- Lockwood TE. Lower-body lift. *Aesthetic Surg J Am Soc Aesthetic Plastic Surg* 2001;21:355–70.
- Le Louarn C, Pascal JF. Autologous gluteal augmentation after massive weight loss. *Plast Reconstr Surg* 2008;121:1515–6. author reply 6–7.
- Pascal JF, Le Louarn C. Remodeling bodylift with high lateral tension. *Aesthetic Plast Surg* 2002;26:223–30.
- Aly AS, Cram AE, Heddens C. Truncal body contouring surgery in the massive weight loss patient. *Clin Plastic Surg* 2004;31:611–24. vii.
- Hurwitz DJ, Agha-Mohammadi S, Ota K, Unadkat J. A clinical review of total body lift surgery. *Aesthetic Surg J Am Soc Aesthetic Plastic Surg* 2008;28:294–303. discussion 4–5.
- Aly A, Mueller M. Circumferential truncal contouring: the belt lipectomy. *Clin Plastic Surg* 2014;41:765–74.
- Richter DF, Stoff A. Circumferential body contouring: the lower body lift. *Clin Plast Surg* 2014;41:775–88.
- Van Geertruyden JP, Vandeweyer E, de Fontaine S, Goldschmidt DP, Duchateau J. Circumferential torsoplasty. *Br J Plast Surg* 1999;52:623–8.
- Maladry D, Pascal JF. Outline surgery after massive weight loss or gastroplasty. *Ann Chir Plast Esthet* 2003;48:405–11.
- Shermak MA, Chang D, Magnuson TH, Schweitzer MA. An outcomes analysis of patients undergoing body contouring surgery after massive weight loss. *Plastic Reconstr Surg* 2006;118:1026–31.
- Jones BM, Toft NJ. Bodylifting: indications, technique and complications. *J plastic Reconstr aesthetic Surg* 2008;61:730–5.
- Agha-Mohammadi S, Hurwitz DJ. Nutritional deficiency of post-bariatric surgery body contouring patients: what every plastic surgeon should know. *Plast Reconstr Surg* 2008;122:604–13.
- Shermak MA. Hernia repair and abdominoplasty in gastric bypass patients. *Plastic Reconstr Surg* 2006;117:1145–50. discussion 51–2.
- Constantine RS, Davis KE, Kenkel JM. The effect of massive weight loss status, amount of weight loss, and method of weight loss on body contouring outcomes. *Aesthetic Surg J Am Soc Aesthetic Plastic Surg* 2014;34:578–83.
- Kitzinger HB, Cakl T, Wenger R, Hacker S, Aszmann OC, Karle B. Prospective study on complications following a lower body lift after massive weight loss. *J plastic Reconstr Aesthetic Surg* 2013;66:231–8.
- Nemerofsky RB, Oliak DA, Capella JF. Body lift: an account of 200 consecutive cases in the massive weight loss patient. *Plast Reconstr Surg* 2006;117:414–30.
- Pilone V, Vitiello A, Borriello C, Gargiulo S, Forestieri P. The use of a fibrin glue with a low concentration of thrombin decreases

- seroma formation in postbariatric patients undergoing circular abdominoplasty. *Obes Surg* 2015;**25**:354–9.
26. Koller M, Hintringer T. Circumferential superficial fascia lift of the lower trunk: surgical technique and retrospective review of 50 cases. *J plastic Reconstr Aesthetic Surg* 2012;**65**:433–7.
 27. Pascal JF, Le Louarn C. Bodylift complications. *Ann Chir Plast Esthet* 2004;**49**:605–9.
 28. Matarasso A, Swift RW, Rankin M. Abdominoplasty and abdominal contour surgery: a national plastic surgery survey. *Plast Reconstr Surg* 2006;**117**:1797–808.
 29. Wilson JA, Clark JJ. Obesity: impediment to postsurgical wound healing. *Adv Skin Wound Care* 2004;**17**:426–35.
 30. Hatef DA, Kenkel JM, Nguyen MQ, et al. Thromboembolic risk assessment and the efficacy of enoxaparin prophylaxis in excisional body contouring surgery. *Plast Reconstr Surg* 2008;**122**:269–79.
 31. Coon D, Gusenoff JA, Kannan N, El Khoudary SR, Naghshineh N, Rubin JP. Body mass and surgical complications in the post-bariatric reconstructive patient: analysis of 511 cases. *Ann Surg* 2009;**249**:397–401.
 32. Garcia Hidalgo L. Dermatological complications of obesity. *Am J Clin Dermatology* 2002;**3**:497–506.
 33. Light D, Arvanitis GM, Abramson D, Glasberg SB. Effect of weight loss after bariatric surgery on skin and the extracellular matrix. *Plast Reconstr Surg* 2010;**125**:343–51.
 34. van Huizum MA, Roche NA, Hofer SO. Circular belt lipectomy: a retrospective follow-up study on perioperative complications and cosmetic outcome. *Ann Plast Surg* 2005;**54**:459–64. discussion 65–6.
 35. Buchanan PJ, Nasajpour H, Mast BA. Safety and efficacy of outpatient lower body lifting. *Ann Plast Surg* 2013;**70**:493–6.